

OCULAR SIDE-EFFECTS OF SYSTEMIC MEDICATIONS

**Bruce E. Onofrey, OD, RPh, FAAO
Professor, UH
Houston, TX**

Questions??

EYEDOC3@AOL.COM

HEY DOC-EVERYTHING LOOKS BLUE!

- 71 Y/O male for general exam complains of occasional color disturbance associated with “migraine-like” HA
- Occurs X 2 months-”at night”
- No prior HX of vascular HA
- No decrease or loss in vision
- No hx TIA

Viagra-The Bad

- Has produced anterior ischemic neuropathy
- Has produced pupil-sparing third nerve palsy
- Associated with ocular vascular events
- Vascular adverse effects increase dramatically when used with nitrates

45 y/o mildly retarded male patient presents for general exam-Patient’s guardian says that medical panel requires patient to have an eye exam every 6 months because of his medications

Bottom Line

*Do a baseline evaluation and recheck patient every 6 months for 1 year, then yearly thereafter
Keep an eye on the literature*

The Breast Cancer Wonder Drug

- Reduces incidence of breast cancer by up to 75%
- Originally used in elderly, post-menopausal women to prevent recurrence of cancer
- Now in young women for prophylaxis
- Produces vision loss?

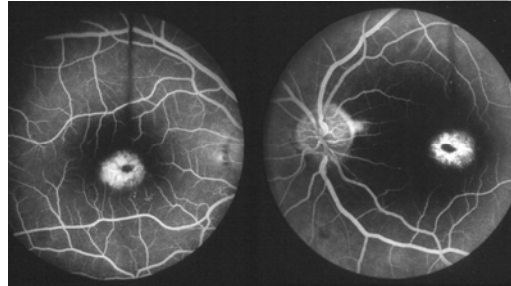
Tamoxifen Maculopathy @ @ @ @

- Occurs in 6% of patients within 6 months of low dose therapy (20mg/D)
- Reversible early, not reversible later
- White crystalline macular deposits
- Nobody knows about this

Patient Management

- Pre-TX baseline evaluation with emphasis on macular function and appearance
- Evaluate every 6 months thereafter or prn decrease in central acuity
- Also monitor for cataract @ @ @ @

What About Plaquenil “Bulls-eye” Maculopathy



FUGEDABOUTIT!!! (Maybe)

- Almost non-existent
- Hydroxychloroquine much safer than chloroquine if daily dose under 750mg (average dose is 400mg/D)
- Very popular for rheumatoid arthritis
- Do baseline and check yearly
- Know your cumulative dose (CU)

Hydroxychloroquine, dosage parameters and retinopathy.

Spalton DJ, Verdon Roe GM, Hughes GR

Department of Medical Ophthalmology, St. Thomas' Hospital, London, U.K.

In a study designed to determine the presence of retinopathy in patients taking hydroxychloroquine we compared 82 patients attending a rheumatology clinic who had taken hydroxychloroquine for over 1 year with controls. Outcome measurements included fundoscopy, fundus photography and automated computerized visual fields of the macular area. No patient was found to have retinopathy. No correlation could be found between indices of visual field function and total drug usage, average daily dose, dosage in mg/kg body weight or duration of treatment. Retinopathy is unlikely to occur at dosages of hydroxychloroquine of less than 6.5 mg/kg body weight with under 10 years of treatment. Present guidelines for ophthalmic screening of patients on antimalarial therapy are too rigorous and visual field testing if not of benefit. Further recommendations are made for ophthalmic supervision.

Retinal toxicity in long term hydroxychloroquine treatment.

Mavrikakis M, Papazoglou S, Sfikakis PP, Vaiopoulos G, Rougas K

Department of Clinical Therapeutics, 'Alexandra' Hospital, Athens, Greece.

. RESULTS: Among 58 patients receiving hydroxychloroquine for more than six years, two relatively young women (3.5%), one treated for RA and the other treated for SLE, developed characteristic hydroxychloroquine related toxic retinal lesions after cumulative doses of 700 g (6.5 years) and 730 g (8 years) of hydroxychloroquine, respectively. Bilateral visual acuity was 6/6 and 6/7.5, respectively; both patients had normal colour perception. Despite an early diagnosis and cessation of treatment, permanent visual field paracentral scotomata in both patients, and persisting lesions in fluorescein angiography in the patient with SLE, were observed at 4.5 and 3 years of follow up, respectively. No other specific cases of hydroxychloroquine related retinopathy have to date been identified in the remaining 302 patients.

CONCLUSION: Cases of irreversible, hydroxychloroquine related retinopathy in patients who did not receive overdoses have not been reported previously. The present observations in two relatively young patients should raise our concern regarding the long term usage of an increasingly popular medication in rheumatology practice.

The Super Fat Blocker- XENICAL

- **Blocks 30% of ingested fats**
- **Can produce flatulence**
- **Uncontrolled bowel movements**
- **During exam-**
- **KEEP THE DOOR OPEN**
- **Have Junior partner do exam**

Xenical and the Eye

- **Inhibits fat soluble vitamin absorption**
- **Vitamins A and E/ Antioxidants**
- **Increased risk of ARMD??/cataract**
- **Manufacturer suggests multivitamin supplement daily.**
- **ARED study proved that nutrition affects course of ARMD**

The Desperate Contact Lens Patient

- **Teenage girl-I will not wear glasses-Wants green, "30 day" lenses**
- **Acne**
- **Allergies-Penicillin/sulfa**
- **Asthma**

- **PEH: Frequent "pink eye"**

- **Meds:**

Topical Benzoyl peroxide

Accutane PO

Ovral 28

Visine 3-4 times daily

Management?

- **Fit with CL's**
- **-What kind??**
- **Drug Side-effects?**
- **Treatment?**

Cardiovascular Agents

- Diuretics
- Cardiac glycosides
- Nitrates
- Anti-Arrhythmics
- Ca⁺⁺ channel blockers
- Beta-blockers
- ACE inhibitors

Cardiac Hemodynamics

- Contractility-Intropy
- Cardiac Output
- Peripheral resistance

- Lose salt and H₂O @@@@
- Renal physiology
- Thiazide-Sulfa
- Loop = Potent
- K⁺ sparing
- CAI's = Sulfa
- New CAI dose
- Osmotics = Sugar?
- Angle closure mechanism? @@@@ @@@@

Diuretics

The Hallucinating Senior Citizen

- 72 y/o male - Visual disturbance @@@ "Lights look like covered in snow with halos"
- Vision getting blurry X 2 months
- Told by primary care doc to get new glasses

Anti-anginal Agents

- Nitrates
- Coronary artery dilators

THE CASE OF THE CLOUDED CORNEA

- 64 y/o male without complaints
- BVA: 20/25 OU
- Meds: Cholestyramine resin-Lipids
Niacin-Lipids
Cordarone-Arrhythmia
Lasix-Hypertension
- SLE: "Strange corneal deposits"

Watch for the anti-arrhythmic Agents @ @ @ @

- All can produce reversible decrease in acuity
- Optic neuritis has occurred
- Permanent loss of vision with amiodarone

Adverse Effects

- Mydriasis
- Blurred Vision @ @ @ @
- Night Blindness @ @ @ @
- Decreased Color Vision
- Optic Neuritis @ @ @ @
- Diplopia
- Verticillata

The Bespeckled Bleeder

- 66 y/o white male
- Bloody OD discovered this AM
- Daily nose bleeds
- bruises on arms X 2 weeks
- His eye doctor says that this is normal

If they like to drink, skip the Tylenol

- Acetaminophen contraindicated in alcoholics
- Can not exceed 4gm/day in normal adults
- Liver failure produces excessive bleeding @ @ @ @

Clotting Tests

- APTT: Activated partial thromboplastin time-Monitor heparin and warfarin
- PT: Prothrombin time-Monitor Warfarin
- INR: Combination of both

Calcium Channel Blockers

- Mechanism-Vasodilation
- Multiple uses
- Value in low-tension GLC???
- Side-effects:
Amplify beta-blocker SE's
Potentiate bleeding with ASA
- Diltiazem and verapamil most common agents

Systemic Beta-Blockers

- Betaxolol
- Propranolol
- Timolol
- Carteolol
- Acetbutolol
- Atenolol
- Labetolol

Beta-Blocker Indications

- Hypertension
- Angina
- Arrhythmia
- Migraine
- Anxiety

Name 8 potentially fatal Beta-blocker Adverse Effects

- Adverse Effects
 1. Asthma
 2. Coronary insufficiency
 3. Heart block/arrhythmia
 4. Depression
 5. Diabetics
 6. Anaphylaxis reversal
 7. Lipid abnormality in coronary artery disease
 8. Impotence (just feel like you want to die)

On-going patient evaluation is critical

- 10% of patients have obvious contraindications to beta-blockers
- 12% of “normals” will develop significant side-effects that will require discontinuation of TX
- Good VS Bad side-effects

Very Popular for BP Control

- Slow the heart rate (Bradycardia)@@@
- Dilate arteries-Lower BP/Decreased perfusion@@@
- Reduced cardiac work load (Decreased cardiac output/ischemia)@@@
- Decreased cardiac sensitivity (Heart block/1st/2nd, 3rd degree
- P---QRS----T)

Combining Topical Beta Blockers with Oral Beta Blockers

- Not a good idea
- Increase in side-effects@@@
- More severe side-effects@@@
- Less topical efficacy@@@

Anti-Hypertensive Therapy

- Proper Staging
- Stepped Care
- Combination
Therapy-Synergy
- Sound familiar to
something else?

A.C.E. Inhibitors (NOT ACE VENTURA) THE -PRILS

- Captopril
- Enalapril
- Lisinopril

ANTI-HYPERTENSIVES

Anti-adrenergics-act peripherally-reduction in peripheral resistance

- Reserpine
- Guanethidine
- Prazosin

Hyperlipidemia

Lipids:

- Cholesterol
- Triglycerides

Lipoproteins

- Chylomicrons
- VLDL, ILDL, LDL, HDL

Anti-hyperlipidemic Agents

Bile Acid Sequestrants:

- Cholestyramine

HMG-CoA Reductase Inhibitors

- Lovastatin
- Pravastatin
- Simvastatin

Cataracts??????????

Accelerated Lipid Metabolism

- Probucol
- Clofibrate
- Dextrothyroxine
- Gemfibrozil
- Nicotinic Acid

Plasma Lipid Effects of Topical Timolol	
Results	
Parameter	Change
Total cholesterol	NS
LDL cholesterol	NS
Triglycerides	+12% ($P=0.07$)
HDL cholesterol	-9% ($P<0.001$)
Total cholesterol/HDL ratio	+8% ($P<0.02$)
N=28	

The Case of the “Sugar Free” Patient

- 67 Y/O male with a complaint of red, mildly tender OD X 3 D
- PEH: Occurred several times in the last 3 years. Tx'd successfully with eye drops from previous eye doctor
- Med Hx: Hypertension and Type II diabetes
- Meds: Diabinese, Lasix and Inderal

Objective

- Sectoral Injection OD
- Blanches with 2.5% phenylephrine
- DX??
- EXCELLENT!!
You're correct
- Episcleritis
- TX: FML TID
- Ibuprofen 600mg QID

The Bad News

Three days later the patients internist calls and he's as mad as hell. I quote “Are you trying to kill my patient”-End of quote.

Patient sent to hospital after collapsing with blood sugar of 30

WHAT HAPPENED?

Diabetes and NSAIDS:More Bad News

- Prostaglandins produce vasodilation of afferent arterioles that supply the unit of the kidney, the nephron. Dilate afferent arteriole increase renal filtration.
- Nsaids produce constriction of afferent arteriole and compromise renal function@@@
- Deadly in diabetics

Reference Material

Facts and Comparisons